

## **Hair Restoration by Follicular Hair Unit Transplantation**

AHMED ALI MAHMOUD, M.D.

*The Department of Plastic Surgery, Faculty of Medicine, Ain Shams University.*

### **ABSTRACT**

Natural hair transplantation has many evolutions over the last fifty years. Histological and anatomical study of the human scalp hairs improved the understanding of the concept of follicular hair unit biology. The follicular unit is a three dimensional block of skin bearing group of hair follicles, sweat, and sebaceous glands that are anatomical and biological related. Disturbance of the follicular unit anatomy ultimately jeopardizes the growth of hair follicles. Thirty-six male patients with variable degrees of baldness underwent hair transplantation. Twenty patients underwent follicular hair unit transplantation while sixteen patients had minigrafting and micrografting. Follicular hair unit transplantation resulted in excellent hair restoration in terms of survival, quality and density. Transplantation of hair minigrafting and micrografting resulted in hair restoration with less survival, weak brittle hairs and low density. This study concluded that preservation of the follicular hair unit in hair transplantation keep the natural biology of hair re-growth and survival.

### **INTRODUCTION**

Interest in hair transplantation will probably increase as knowledge that the most modern hair-transplantation techniques can create virtually undetectable restorations spreads. To this day, hair transplantation remains the treatment of choice for most patients with hair loss. In the 1950s, surgeons such as Orentreich, Stough, and others, pioneered the earliest hair-transplant procedures [1,2,3]. Although these early procedures resulted in hair growth on bald scalps, they were characterized by obvious pluglike appearances. However, the early experiences formed the foundation for hair transplant procedures, that is, the donor dominance of hair-bearing scalp to grow hair after it is transplanted into another part of the scalp as an autograft.

Surgical hair restoration has followed a logical course to follicular unit transplantation. The concept of redistributing hair in naturally occurring units of 1-4 hairs exactly as nature grows it should have been recognized and used by the hair transplant community earlier than 1988. The finding that hair grows in naturally occurring groupings of 1-4 (and rarely, more hair) has been known for many years.

The histopathologic definition of the follicular unit was defined clearly by Headington in 1984 [4].

Nevertheless, modern surgical hair restoration techniques ranging from Orentreich's description of punch autografting in 1958 [1] to Limmer's first use of follicular units in 1988 were completed via unnatural groupings of nature's building blocks, resulting in a recognizable pluggy product [5].

By definition, follicular unit transplantation is the redistribution of naturally occurring follicular groupings (follicular units) to the bald zone. The groupings are removed from the donor area by single-bladed elliptical excision and carefully and microscopically dissected beneath the binocular stereoscope [6]. The donor tissue is trimmed into follicular units, removing the bald tissue between the units that contains no hair follicles. Then, the follicular units are reimplanted into the bald recipient zone using a needle tunnel or small slit incision. To minimize damage to the recipient vascular supply essential to the survival of grafts, bald tissue is not removed from the recipient zone. Relatively dense packing during the first session is usual (20-30 grafts per cm<sup>2</sup>) to create a cosmetic result that can stand on its own if no further procedure sessions are completed [7].

This study was designed to examine the efficacy of follicular unit hair transplantation technique in restoration of hair with good natural appearance in comparison with the classical hair minigrafting and micrografting techniques.

### **PATIENTS AND METHODS**

This study included thirty-six male patients who had variable degrees of hair loss. The age of the patients was ranged from 24 to 43 year old with an average of 33.4 years. The study was done in the department of plastic surgery, Ain Shams University from February 2002 to September 2006 with an average follow-up period of 30 months.

Twenty patients had follicular hair unit transplantation. Sixteen patients had minigrafting and micrografting hair transplantation.

Techniques:

*Follicular hair unit transplantation:*

The technique consists basically of three steps that are performed by the hair transplant team. The team includes two assistant doctors and two nurses. The first step was the harvest of hair strip from the parieto-occipital area. The donor area was marked and shaved. The width of the planned donor strip depends on the amount of follicular hair units needed. Local 0.5% xylocaine and epinephrine 1:100 000 was infiltrated at the donor area. The local anesthetic infiltration was given to the point it makes the donor area swollen and turgid. The strip was harvested by multibladed scalpel which split the strip into multiple slices of skin bearing hair in situ. The strip was harvested including the subcutaneous fat. After harvesting the strip, homeostasis was done. Excessive cautery was avoided to prevent postoperative alopecia at the donor site. Subcutaneous galeal monocryl 4/0 sutures and a skin continuous prolene 3/0 suture were taken.

The second step consists of simultaneous preparation of the follicular hair units and recipient bald skin. The donor skin bearing hair was divided into the slices of skin by sharp sterile shaving blades. Throughout the procedure, the hairs were kept wet in putrid dish filled with saline. The skin strip was put on silicone board and trimming of subcutaneous fat was done. Under magnifying lamp (4X) and with sharp shaving sterile blade the follicular units were separated individually (Fig. 1). The follicular hair units were put on wet gauze and arranged in rows to facilitate their counting and manipulation. Simultaneously, the recipient area was infiltrated with lidocaine/epinephrine 1:00 000. Punching of the bald skin was done by electric powered drill. The size of the punches varied from 1.2mm to 1.8mm. Smaller size punch drill punches were used to punch the skin at the anterior hair line while bigger sized drill punches were used to make bigger holes posterior. The number of punches should be equal or slightly less than the number of follicular hair units prepared. After completion of punching the bald skin, ice bag wrapped in gauze was put on the skin to help homeostasis.

The third step was the implantation of follicular hair units into the holes that created in the recipient area. Care was experienced in manipulation of the follicular grafts. The jeweler forceps grasped the unit from the epidermal side only. Grasping of the follicular root may results in crushing of hair and

jeopardizes its survival. Smaller follicular units were implanted at the anterior hair lines while bigger units were implanted posterior. The follicular units were implanted without crushing, twisting, and/or kinking. The recipient scalp was irrigated by saline every three minutes during implantation to keep the hair units always wet. Care was taken that all implanted units were well fitted in the holes and at the same level of the epidermis. After completion of implantation, sofra tull impregnated with an antibiotic ointment was securely applied over the transplanted hair units. Light bandage of the whole scalp was applied for five days.

*Minigrafting and micrografting:*

All patients were operated upon by local xylocaine infiltration mixed with 1:100000 adrenaline at the hair donor site and the bald area. Minigrafting and micrografting were harvested from the parieto-occipital area by 1.5 and 2mm skin pinch needles. Hair grafts were put on saline-wet gauze and they were kept wet throughout the procedure. Bald area was marked for the anterior hair line and the distribution of the implantation. Creation of holes in the bald area was done by 1.2 and 1.5mm skin pinch needles. Space was lift between every two holes that equal the size of the used skin pinch needle. After completion of scalp holes, hemostasis was done by application of ice packs. Micrografts bearing one to two hairs were implanted at the anterior hair line. Minigrafts bearing more than two hairs were implanted posterior. After completion of implantation of all minigrafts and micrografts, sofra tull impregnated with antimicrobial ointment was applied on the implanted hair grafts as well as the donor site. Dressing and light bandage was applied.

## RESULTS

Evaluation of the results was done throughout 18-month follow-up. Close-up photographs were taken before surgery. All patients were photographed six months and one year after surgery. Follicular hair unit transplantation gave excellent results in terms of survival, density and quality of growing hair (Figs. 2A,B; 3A,B; 4A,B).

Sixteen patients underwent hair transplantation by minigrafting and micrografting. Hair grew in all patients. However, the transplanted growing hairs were weak sparse and of low density. Close-up observation revealed loss of a variable amount of the transplanted hairs. Furthermore, the transplanted minigrafts appeared prominent over the surface of the scalp that gave unnatural look (Figs. 5A,B, 6).

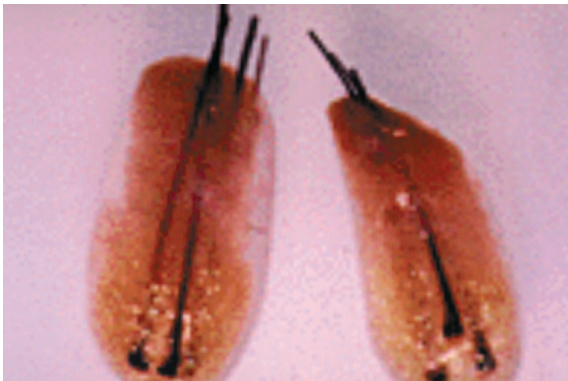

Fig. (1): Dissected individual hair until: Note the grouping of two to three hairs in close anatomical relation.

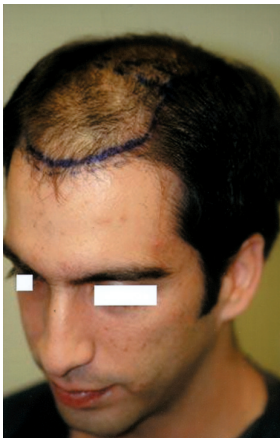

Fig. (2-A): 30-year old male with frontal baldness.

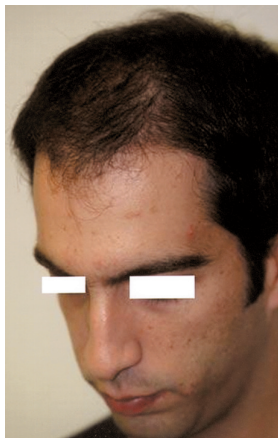

Fig. (2-B): One-year after follicular hair unit transplantation.

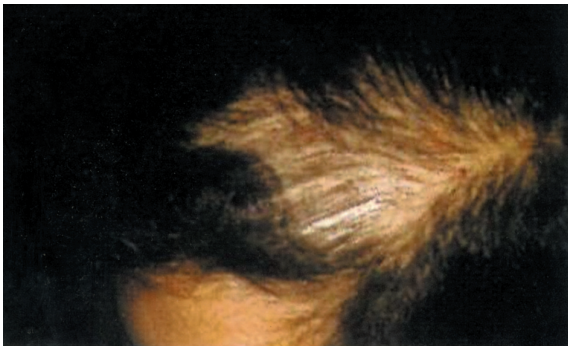

Fig. (3-A): 27-year old male patient with Baldness of vertex area.

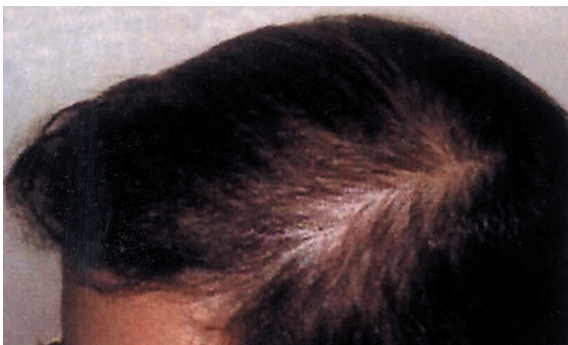

Fig. (3-B): One-year after follicular hair unit transplantation.

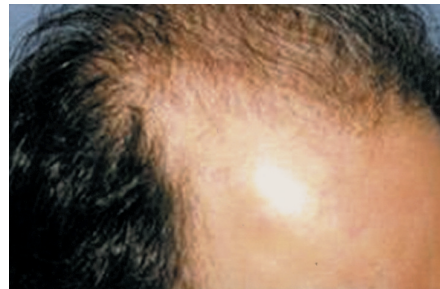

Fig. (4-A): 37-year old male with baldness of frontal area.

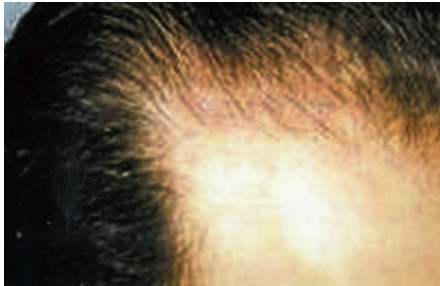

Fig. (4-B): One-year after follicular hair unit transplantation.

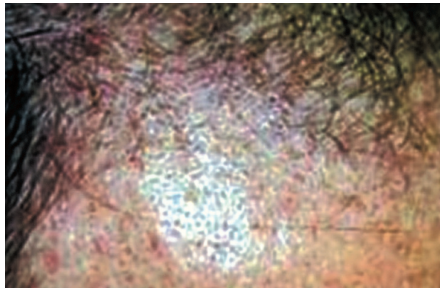


Fig. (5-A): 34-year old male with baldness of frontal area.

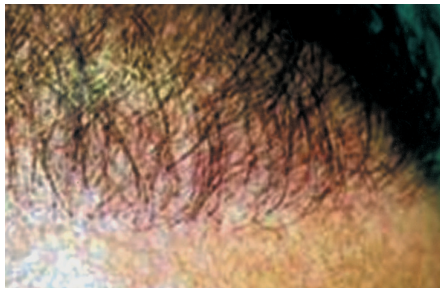


Fig. (5-B): One-year after hair transplantation by minigrafting and micrografting. The hairs are sparse and of low density.

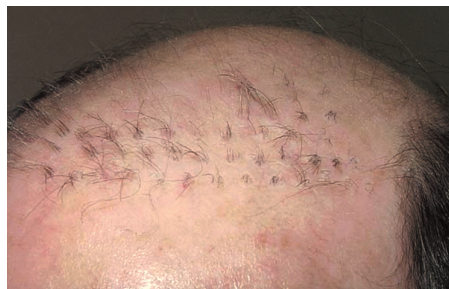

Fig. (6): 36-year old male with baldness. Hair transplantation by mini and micrografting one-year postoperative. The hair is weak, sparse, low density with unnatural look.

## DISCUSSION

The doll's-hair, or plug like, appearance was the result of using grafts typically 4mm in diameter. These plugs contained 15-20 hairs and were usually harvested with a circular punch, then transplanted into 4-mm circular recipient sites in the bald scalp. Once transplanted, hairs entered a 4-month dormant cycle (telogen), after which they began continued growth for as long as donor site hair grew [1].

From the 1950s until the early 1990s, plug-graft transplantation was, with few exceptions, the most common hair-transplant procedure. Small grafts, created by halving or quartering the formerly standard 4-mm plug grafts became popular in the early 1980s [4,8]. Over the last 15 years, developments in hair transplantation have followed this evolution toward smaller grafts to mimic the way hair grows naturally on the scalp [7].

Until the last several years, with the popularization and further development of microscopic follicular-unit grafting, state-of-the-art hair transplantation involved transplanting a combination of minigrafts and micrografts. These 2 terms are open to definition, but a typical micrograft contains 1-2 hairs, whereas a minigraft contains 3-6 hairs. Combining these different-sized grafts by placing the micrografts along the hairline and the minigrafts further behind gives the surgeon a tool that potentially makes a hair transplant difficult to detect. Artistry, individualization of the specific procedure to the patient, and other variations in technique are of critical importance [6,9].

The key to follicular unit hair transplantation is to identify hair groupings, dissect the follicular units of hair from the surrounding tissue and then place these units in the recipient site in a density and location appropriate for a mature individual. Introduction of follicular unit hair transplantation and the use of the binocular microscope can increase the growth of replacement hair up to 20% [6].

Limmer in 1994 [5] reported loss of a considerable number of the transplanted hair by minigrafting that resulted in low density of the growing hair.

Furthermore, Limmer [5] noted cobblestone appearance of the transplanted hair that gave the scalp unnatural appearance. Five years later Limmer [6] studied the follicular hair unit transplantation and reported better results in terms of better survival of transplanted units that led to higher density. In this study, we reported higher survival of follicular hair units after transplantation. This technique avoided much tissue reaction that usually results in cobblestone appearance. The explanation of better result with follicular hair unit transplantation may be the undisturbed biology of the follicular unit that augments the survival and growth of the transplanted hairs.

In conclusion, follicular hair unit transplantation gave better survival of the transplanted hair with a satisfactory high density of restored hair. Being biological, wound healing is superior than other techniques that disturb the biology of the follicular unit.

## REFERENCES

- 1- Orentreich N.: Autografts in alopecias and other selected dermatological conditions. *Ann. N Y Acad. Sci. Nov.*, 20 (83): 463-79, 1959.
- 2- Stough D.B. and Haber R.S.: *Hair replacement: Surgical and Medical*. St Louis: Mosby, 1996.
- 3- Vallis C.P.: Surgical treatment of the receding hairline. *Plast. Reconstr. Surg. Sep.*, 44 (3): 271-8, 1969.
- 4- Headington J.T.: Transverse microscopic anatomy of the human scalp. A basis for a morphometric approach to disorders of the hair follicle. *Arch. Dermatol. Apr.*, 120 (4): 449-56, 1984.
- 5- Limmer B.L.: Elliptical donor stereoscopically assisted micrografting as an approach to further refinement in hair transplantation. *J. Dermatol. Surg. Oncol. Dec.*, 20 (12): 789-93, 1994.
- 6- Limmer B.L. and Buchwach K.A.: Hair transplantation using follicular unit micrografting. *Facial Plast. Surg. Nov.*, 7 (4): 523-35, 1999.
- 7- Norwood O. and Limmer B.L.: Advances in hair transplantation. *Adv. Dermatol.*, 14: 89-113; Discussion 114.
- 8- Bradshaw W., Unger W.P., Norstrom R.E.A., eds: *Quarter-grafts; A technique for minigrafts*. In: *Hair transplantation*. 2<sup>nd</sup> ed. Marcel Dekker, 333-51, 1988.
- 9- Bernstein R.M., Rassman W.R. and Szaniawski W.: Follicular transplantation. *Int. J. Aesthetic. Restor. Surg.*, 3: 119-32, 1995.